

Spring 2015

Outcomes of a Comprehensive Physical Therapy Treatment Program for a 22-Year-Old Patient with Migraine Without Aura, Chronic Migraine, and Cervicogenic Type Headache: A Case Report

Katrina L. Koltz
Governors State University

Follow this and additional works at: <http://opus.govst.edu/capstones>

 Part of the [Physical Therapy Commons](#)

Recommended Citation

Koltz, Katrina L., "Outcomes of a Comprehensive Physical Therapy Treatment Program for a 22-Year-Old Patient with Migraine Without Aura, Chronic Migraine, and Cervicogenic Type Headache: A Case Report" (2015). *All Capstone Projects*. 105.
<http://opus.govst.edu/capstones/105>

For more information about the academic degree, extended learning, and certificate programs of Governors State University, go to http://www.govst.edu/Academics/Degree_Programs_and_Certifications/

Visit the [Governors State Physical Therapy Department](#)

This Project Summary is brought to you for free and open access by the Student Capstone Projects at OPUS Open Portal to University Scholarship. It has been accepted for inclusion in All Capstone Projects by an authorized administrator of OPUS Open Portal to University Scholarship. For more information, please contact opus@govst.edu.

**OUTCOMES OF A COMPREHENSIVE PHYSICAL THERAPY TREATMENT
PROGRAM FOR A 22-YEAR-OLD PATIENT WITH MIGRAINE
WITHOUT AURA, CHRONIC MIGRAINE, AND
CERVICOGENIC TYPE HEADACHE:
A CASE REPORT**

By

Katrina L. Koltz, SPT

A.S., Moraine Valley Community College, 2008

B.A., Trinity Christian College, 2012

CAPSTONE PROJECT

Submitted in partial fulfillment of the requirements

For the Degree of Doctor of Physical Therapy

Governors State University
University Park, IL 60484

2015

ABSTRACT

Background and Purpose: The purpose of this case report is to describe the interventions and outcomes of a comprehensive physical therapy (PT) treatment program that emphasized addressing musculoskeletal deficits and increasing neuromuscular control, which was theorized to decrease headache (HA) symptoms for a patient with overlapping HA diagnoses.

Case Description: The subject was a 22-year-old Caucasian female with an 8-year history of migraine without aura, chronic migraine, and cervicogenic type headaches. A comprehensive PT program was implemented to address subject's musculoskeletal deficits, neurological impairments, and functional limitations. Assessments were performed at initial evaluation and two weeks later at re-assessment. Outcome measures utilized were the Headache Disability Inventory (HDI), the Neck Disability Index (NDI), manual muscle testing (MMT), cervical range of motion (ROM) as well the subjective report of HA frequency, duration, and intensity, prescription drug use, and achievement of functional goals.

Outcomes: At the conclusion of the two-week PT program, the subject improved her "worst" HA intensity, cervical ROM and strength, perceived disability scores, and decreased prescription drug use. The subject was able to obtain part-time employment and take community college classes.

Discussion: The findings support the hypothesis that it is possible to influence HA symptoms with a comprehensive PT program that directly addresses the subject's functional limitations, musculoskeletal deficits, and neuromuscular integration to positively influence one's quality of life and perceived disability despite complex and overlapping HA diagnoses.

INTRODUCTION

Headache or pain in the head was the 5th leading cause of emergency department visits in the United States in 2009.¹ The International Headache Society's (IHS) International Headache Classification (ICHD-2) system promotes standardized HA classification, diagnosis, and treatment in research and clinical practice. This classification system separates headaches into 14 major categories and 129 subcategories and can be classified as 1) primary, resulting from vascular or muscular origin, 2) secondary, resulting from another source such as inflammation or head and neck injuries, or 3) cranial neuralgias, central and primary facial pain, and other headaches.²

Given the complex nature of headaches, migraines, and individual patient presentations, symptoms often overlap and make clinical diagnosis difficult. Cervicogenic headaches fall into this category as they have been found to have similar characteristics as migraine without aura and chronic migraine headaches.² The IHS criteria for the relevant HA presentations are provided in Table 1 and demonstrate how the subject's symptoms overlapped into multiple HA categories.

Table 1: Headache Classification Criteria According to the International Headache Society's International Headache Classification II ²

| Primary Headaches | | Secondary Headaches |
|-------------------------------------------------------------------------------------------------------------|---------------------------------------------------------------------------------------------------------------------|--------------------------------------------------------------------------------------------------------------------------|
| <i>Migraine Without Aura</i> | <i>Chronic Migraine</i> | <i>Cervicogenic</i> |
| A. At least 5 attacks fulfilling criteria B-D B. Headache attack lasting 4-72 hours and occurring on <15 | A. Headache (tension-type and/or migraine) on ≥15 days/month for at least 3 months B. Occurring in a patient who | A. Pain referred from source in neck and perceived in one or more areas of head and/or face, fulfilling criteria C and D |

| | | |
|-------------------------------------------------------------------------------------------------------------------------------------------------------------------------------------------------------------------------------------------------------------------------------------------------------------------------------------------------------------------------------------------------|----------------------------------------------------------------------------------------------------------------------------------------------------------------------------------------------------------------------------------------------------------------------------------------------------------------------------------------------------------------------------------------------------------------------------------------------------------------------------------------------------------------------------------------------------------------------------------------------------------------------------------------------------------------------------------------------------------------------------------------------------------------------|------------------------------------------------------------------------------------------------------------------------------------------------------------------------------------------------------------------------------------------------------------------------------------------------------------------------------------------------------------------------------------------------------------------------------------------------------------------------------------------------------------------------------------------------------------------------------------------------------------------------------------------------------------------------------|
| <p>days/month</p> <p>C. Headache has at least two of the following characteristics: unilateral location, pulsating quality, moderate or severe pain intensity, aggravated by or causing avoidance of routine physical activity</p> <p>D. During headache at least two of the following: nausea, vomiting, photophobia, phonophobia, osmophobia</p> <p>E. Not attributed to another disorder</p> | <p>has had at least five attacks fulfilling criteria for 1.1 Migraine without aura</p> <p>C. On ≥ 8 days per month for at least 3 months headache has fulfilled C1 and/or C2 below, that is, has fulfilled criteria for pain and associated symptoms of migraine without aura</p> <p>a. Has at least two of the following: unilateral location, pulsating quality, moderate or severe pain intensity, aggravation by or causing avoidance of routine physical activity and at least one of the following: nausea and/or vomiting, photophobia and phonophobia</p> <p>b. Treated and relieved by triptan(s) or ergot before the expected development of C1 above</p> <p>D. No medication overuse and not attributed to another causative disorder</p> | <p>B. Clinical, lab and/or imaging evidence of disorder/lesion within the c-spine or soft tissues of the neck known to be, or generally accepted as, a valid cause of headache</p> <p>C. Evidence that the pain can be attributed to the neck disorder/lesion based on at least one of the following:</p> <ol style="list-style-type: none"> 1. Demonstration of clinical signs that implicate a source of pain in the neck, 2. Abolition of headache following diagnostic blockade of a cervical structure or its nerve supply using placebo <p>D. Pain resolves within 3 months after successful treatment of the causative disorder or lesion</p> |
|-------------------------------------------------------------------------------------------------------------------------------------------------------------------------------------------------------------------------------------------------------------------------------------------------------------------------------------------------------------------------------------------------|----------------------------------------------------------------------------------------------------------------------------------------------------------------------------------------------------------------------------------------------------------------------------------------------------------------------------------------------------------------------------------------------------------------------------------------------------------------------------------------------------------------------------------------------------------------------------------------------------------------------------------------------------------------------------------------------------------------------------------------------------------------------|------------------------------------------------------------------------------------------------------------------------------------------------------------------------------------------------------------------------------------------------------------------------------------------------------------------------------------------------------------------------------------------------------------------------------------------------------------------------------------------------------------------------------------------------------------------------------------------------------------------------------------------------------------------------------|

In 2013, Racicki *et al.* completed a systematic review that assessed the effectiveness of conservative PT management of cervicogenic HA. They reported, "Both cervical manipulation and mobilization, along with exercise, was the most effective conservative intervention for decreasing cervicogenic HA intensity, frequency, and neck pain".³ Another review by Biondi analyzed the safety and efficacy of PT in the treatment and management of primary HA disorders. It was found that PT is unlikely to be

harmful and is most effective in treating migraine in conjunction with other treatments such as thermal biofeedback, relaxation training, and exercise.⁴

PT management and treatment of HA habitually consists of manual or manipulative therapy³⁻⁹, soft tissue massage⁶, postural correction⁵⁻⁸, biofeedback⁴⁻⁸, a variety of therapeutic or strengthening exercises³⁻¹⁰ with a consistent focus on deep neck flexor strength and endurance, and various combinations³⁻⁹ of the aforementioned. While there is research on the efficacy of PT treatment for patients with migraine⁴, cervicogenic headaches^{3,5-7,9-11}, and chronic-tension type headaches^{4,8} individually, there is no known literature that analyzes subjects that present with a combination of HA types. This is a major obstacle when developing evidence based treatment programs for patients with complex and overlapping HA diagnoses.

CASE DESCRIPTION

Subject

The subject was a 22-year-old Caucasian female with an eight-year history of headaches. She was referred to PT upon her mother's recommendation. The subject was in overall good health but was unable to completed activities of daily living (ADLs) such as cooking and cleaning, drive, pursue higher education, maintain employment, or participate in social and community based activities due to HA symptoms. HA symptom location,

frequency, duration, intensity, and additional symptoms are outlined in table 2.

Table 2: Patient History and Initial Examination Tests and Measures Data

| | Pre-surgery | Post-surgery | Initial Evaluation |
|-------------------------------------------|-------------------------------------------------------------------|---------------------------------------------------------------------------------------------------------------------------------------------|----------------------------------------------------------------------------------------------------------|
| HA Location | Suboccipitals | Frontal bone just superior to the supraorbital notch | Primarily on right side, but can occur bilaterally in frontalis, supraorbital notch and surrounding area |
| HA Frequency (# in last 7 days) | 7 | 7 | 7 |
| HA Duration (% of day) | 100 | 100 | 100 |
| HA Intensity (NPRS) (0-10) | 6/10 - 7/10 | 8/10 | Current: 7/10 Best: 4/10 Worst: 10/10 |
| Additional Symptoms | Occasional nausea and emesis and frequent nonvestibular dizziness | Occasional numbness in bilateral suboccipitals and right temple, occasional pain in jaw and ear, and stiffness in bilateral upper trapezius | Photophobia and phonophobia Sleep disturbances unchanged by position changes |

The subject had exhausted a multitude of treatments to address headaches in an attempt to improve her quality of life. Her previous treatments included: nerve decompression surgery (August 2013), Botox injections, previous episode of PT, chiropractic, acupuncture, biofeedback, Ayurveda ®, birth control, progesterone, and various migraine prescription drugs such as Vicodin ® and Topamax ®. Treatments, such as chiropractic, Botox Injections and Vicodin ®, provided temporary symptom relief while

other treatments, such as progesterone and nerve decompression surgery amplified symptoms. Additional symptoms developed after the use of birth control, which caused nausea without HA symptom relief, and Topamax ®, which caused tingling and numbness in bilateral extremities. All treatments were discontinued with the exception of Vicodin ® 300mg p.r.n. taken orally and Botox injections to the supraorbital notch and suboccipital region every 3 months. Imaging (MRI) completed 2 years ago ruled out any abnormalities and pathologies.

With intense HA symptoms, the subject reported frequent episodes of anomia and feeling as though on a “rollercoaster” when supine which caused nausea without emesis. The subject reported HA triggers that included: changes in weather and sleep routine, stress, and missing meals. She also reported an increase in symptoms with moderate to intense activity, most specifically cardiovascular exercise, smells such as onions, light, noise, prescriptions like Excedrin Migraine ®, the week before and during menstruation, and changes in position such as elevators, and ascending and descending stairs.

She managed her symptoms primarily with Vicodin ®, sleep, cryotherapy on forehead, activity avoidance, and strict sleep and meal schedule. She also reported use of a night guard but questioned the efficacy of its use. Subject denied history of seizures. The subject expressed the desire to be able to return to college classes, part time employment,

photography as a hobby, and social activities such as going to the movies and shopping.

Systems Review

Musculoskeletal

A postural assessment of the subject revealed moderate forward head posture, minimal thoracic kyphosis, and bilateral scapular winging. The subject was tender to palpation bilaterally in upper trapezius, medial border and inferior angle of scapula, pectoralis major, anterior scalene, and sternocleidomastoid. Deficits were noted in the subject's cervical ROM and strength. The subject's temporomandibular and shoulder were assessed and found to be unimpaired. A cervical joint mobility assessment exposed significant hypomobility at C2-C3, moderate hypomobility C5-C7, and hypermobility at C4.

Neurological

Monofilament testing of bilateral upper and lower extremities proved unremarkable. Reflexes, myotomes, and dermatomes showed no deficits with standard patient and therapist positioning and measurement technique. Upper Limb Tension Testing (ULTT) was positive for median and ulnar nerve involvement bilaterally. Vestibuloocular Reflex and cranial nerve testing proved unremarkable. Vertebral artery, Alar ligament, and transverse

ligament testing was negative for vertebral basilar insufficiency and upper cervical instability.

Cardiovascular, endocrinologic, and integumentary

There were no significant findings for the cardiovascular and endocrinologic systems. The subject's integumentary system was normal with the exception of minimal scarring noted on the supraorbital ridge bilaterally and the suboccipital region.

Gastrointestinal

The subject reported gastrointestinal tract symptoms of nausea and occasional vomiting with severe HA symptoms.

CLINICAL IMPRESSION 1

The findings from the subject's history and systems review indicated how severely the HA symptoms limited her participation in community and social activities and restricted her contribution to society and higher education. Based on the initial findings in the system's review, a more in-depth assessment was appropriate to further identify functional limitations and deficits. Therefore, tests and measures were performed to assess the subject's HA frequency, duration, and intensity, cervical ROM and strength, perceived disability, and prescription drug use.

Because the subject presented with cervicogenic HA characteristics, it was clear that there was a musculoskeletal component to her HA etiology. Based on the IHS classification system, the subject presented with characteristics of migraine without aura, chronic migraine, and cervicogenic type HA. This unique presentation of HA symptoms in this subject provided an excellent opportunity to add to the body of literature on PT interventions and their outcomes for patients with overlapping HA diagnoses. This supported the plan of care and interventions chosen for the subject.

EVALUATION

Tests and Measures

Headache Frequency

The subject was questioned as to the HA frequency in the last 7 days. Possible scores range from 0-7 days. The lowest possible score of 0 indicated no HA attacks or episodes within the last 7 days and the highest possible score of 7 indicated at least one HA episode per day for the last 7 days. The subject's initial measures are provided in Table 3. While there is no reported psychometrics for this measure, it is a common outcome measure used with HA patients.^{3,5-7,9,12,13}

Headache Duration

The subject was questioned as to HA duration for the past 24 hours. Possible scores range from 0-100% of the day. The lowest possible score of 0% indicated no HA symptoms in the last 24 hours and highest possible score of 100% indicates constant HA symptoms for the last 24 hours. The subject's initial measurements are provided in Table 3. While there is no reported psychometrics for this measure, it is a common outcome measure used with HA patients.^{3,5,13}

Headache Intensity

The subject's HA intensity was measured with the Numeric Pain Rating Scale (NPRS), a scale where 0 indicates no pain at all and 10 is so painful the subject would seek care at an emergency room. The subject was asked to rate her current, best, and worst pain in the past 24 hours. The subject's initial measurements are provided in Table 3. The NPRS is also a standard assessment in PT treatment and management of HA and cervical radiculopathy.^{14,15}

Her symptoms were primarily right sided, but occasionally occurred bilaterally in frontalis, supraorbital notch and surrounding area. She reported her symptoms in the morning as an "ache" with intensity of 4/10 and in the evening as an "intense stabbing" with intensity of 8/10 - 10/10.

A study by Farrar *et al.* determined the minimal clinically important difference (MCID) to be 2 points in patients with chronic pain.¹⁶ The test-retest reliability was excellent for ratings on two or more days during week one compared to two or more days during week two ($r = 0.79 - 0.92$) and increased with increasing numbers of ratings with the highest reliability for four ratings per day taken on seven days ($r=0.95$).¹⁷ Herr *et al.* found excellent interrater reliability with 100% agreement in healthy populations.¹⁸ The internal consistency for patients with chronic pain had excellent internal consistency for a single pair of ratings (one during week 1 and one during week 2) ($\alpha = 0.84$).¹⁷ This study, by Jensen and McFarland, also demonstrated excellent internal consistency for ratings on two or more days during week one compared to two or more days during week two ($\alpha = 0.89 - 0.98$).¹⁷ Excellent internal consistency was also found in healthy patients ages 25-55 years old ($\alpha = 0.88$).¹⁸

Range of Motion

During the initial examination, the subject's cervical active ROM was measured with standard goniometer and inclinometer positioning.¹⁹ Her cervical active ROM was within functional limits with the exception of limitations in flexion and bilateral rotation and pain without loss of motion with extension and left lateral flexion. The subject's initial measurements are provided in Table 3. ROM assessments are important in identifying where

structural and functional limitations are present. Once limitations were recognized, they could be re-assessed over time to demonstrate measureable change. A meta-analysis by Gadotti, *et al.* found that patients with cervicogenic HA have altered cervical ROM in rotation, flexion-extension, and cervical rotation with cervical flexion, which supports the use of ROM measurements in this subject's assessment.¹¹

Muscle Strength

Upper-extremity strength was measured with MMT at the initial examination. Capital flexion which assessed rectus capitus anterior, rectus capitus lateralis, and longus capitus, scapular adduction and downward rotation which assessed the bilateral rhomboids, and shoulder external rotation which assessed bilateral infraspinatus and teres minor were measured to isolate and compare strength of individual muscle groups. The exact subject position and instruction was adapted from Hislop.²⁰ The subject demonstrated some upper trapezius compensation with capital flexion. The subject's initial measurements are provided in Table 3.

A study by Blizzard *et al.* determined the intra-observer reliability for manual testing of the long cervical flexors and extensors. In healthy subjects, the kappa value for flexors was 0.86 and for extensors was 0.78.¹²

Headache Disability Inventory

The HDI measured the subject's perceived disability related to headaches. The HDI consists of 25 items each requiring a "yes" (4 points) "sometimes" (2 points) or "no" (0 points) which are then summed. The score can range from 0-100 with a score of 100 being 100% perceived disability. The subject's initial perceived disability score is provided in Table 3.

A study by Jacobson *et al.* concluded that the HDI had a good internal consistency of 0.89, robust long-term test-retest reliability of 0.83, good construct validity, and the MCID to be a change of at least 29 points.²¹

Neck Disability Index

The NDI is a self-reported questionnaire that was used to determine how neck pain affected the subject's daily life. The NDI consists of 10 items and each question contains six answer choices, scored from 0, which indicates no disability to 5, which indicates complete disability. All sections' scores were totaled, reported on a 0-50 scale, and converted to a percentage (0-100%). Using this system, a score of 10-28% is considered to constitute mild disability; 30-48% is moderate; 50-68% is severe; 72% or more is complete. The subject's initial perceived disability score is provided in Table 3. The NDI has also become a standard outcome measure for patients with cervical radiculopathy, cervicogenic headaches, and neck pain.^{5,6,10,14,15}

McCarthy *et al.* found an excellent Cronbach’s alpha of 0.864 (95% confidence limits 0.825–0.894) and a high test-retest reliability (ICC 0.93, 95% confidence limits 0.86–0.97).²² Cleland *et al.* (2008) found the minimum detectable change to be 19.6% and the MCID to be 19% (both on a scale of 0-100%) in a population with mechanical neck disorders.²³

Prescription Drug Use

All prescriptions taken by the subject were recorded with dosage, frequency, and route of administration. The subject was questioned as to the amount of medication required to manage HA symptoms. Dosage was recorded in milligrams based on subject report of number of pills taken in past 24 hours. Example- 1 pill = 300 mg, 2 pills = 600 mg, etc. The subject’s initial measurements are provided in Table 3.

While there is limited research on the reliability and validity of self-reported prescription drug use, it is useful in determining the subject’s dependence on pharmaceutical interventions to self-manage pain.

Medication intake is also a common alternative outcome measure in HA.^{3,7}

Table 3: Initial Examination Tests and Measures

| | | |
|--------------------------------------------|----------------|-------|
| HA Frequency (# in the last 7 days) | | 7 |
| HA Duration (% of day) | | 100 |
| HA Intensity (NRPS) (0-10) | Current | 7/10 |
| | Best | 4/10 |
| | Worst | 10/10 |
| Cervical ROM | Flexion | 0-45 |

| | | | |
|---------------------------------------|-----------------------------------------------|----------|-------|
| (Degrees) | Extension | | 0-65* |
| | Rotation | R | 0-60 |
| | | L | 0-60* |
| | Lateral Flexion | R | 0-45 |
| L | | 0-45* | |
| Strength (MMT) (0/5 – 5/5) | Capital flexion | | 3/5** |
| | Scapular adduction + downward rotation | R | 3/5 |
| | | L | 3-/5 |
| | Shoulder external rotation | R | 3/5 |
| L | | 3-/5 | |
| HDI (% disability) | | | 86 |
| NDI (% disability) | | | 70 |
| Prescription Drug Use (mg/day) | | | 600 |

* Indicates pain with movement

** Indicates upper trapezius compensation with muscle testing

CLINICAL IMPRESSION 2

Based on the results from the initial examination, there was a musculoskeletal component to the subject's HA symptoms. This is evident through the musculoskeletal and neurological screenings that revealed muscular weakness and compensatory strategies, joint hypomobility, limitations in cervical active ROM, presence of pain with movement, and cervical radiculopathy.

Therefore, based on the subject's complex history, symptoms, and, the impact of those symptoms on her quality of life, the subject was appropriate for a comprehensive PT program because the approach was conservative and posed minimal threat to making the subject's symptoms worse. It was hypothesized that decreased HDI and NDI scores would

positively influence the subject's discharge status and correspond with goal achievement.

Diagnosis

The subject's medical diagnosis was migraine without aura, chronic migraine, and cervicogenic HA. The PT diagnosis was muscle weakness, joint hypomobility, limited cervical ROM, pain, and decreased independence in ADLs.

Prognosis

Although the subject was highly motivated to improve, the current literature does not strongly support PT for HA management. Jull and Stanton conducted a randomized control trial to identify predictors of responsiveness to PT management of cervicogenic HA. Other than the presence of light-headedness indicating poor odds of success, no consistent patterns of predictors were identified.²⁴ Based on this information and the limited amount of time for data collection, the subject had a fair prognosis.

Plan of Care and Goals

The plan of care was to see the subject three times per week for slightly longer than two weeks for a total of seven visits each a one-on-one sessions. Treatment sessions were between 60 and 90 minutes at minimal to

moderate intensity as to not excessively aggravate the subject's HA symptoms. The subject was instructed to perform the home exercise program (HEP) two times per day. The unusually short treatment period was dictated by the author's remaining length of stay at the clinical site.

Goals established with the subject emphasized safety and independence with the subject being able to achieve 70 degrees of pain free cervical rotation in order to look over left shoulder while operating a motor vehicle, ascend and descend 2 flights of stairs without an increase in HA symptoms, complete ADLs such as cooking, cleaning, and gardening without increasing current HA intensity to greater than 7/10, and decrease HA frequency to less than 7 days per week, duration to less than 100% of the day, and intensity to less than 10/10 in order to participate in community and social activities.

INTERVENTIONS

The following interventions were incorporated to address the subject's functional deficits and chief complaints in order to achieve functional goals. Table 4 provides the intervention descriptions and supporting research for study replication. Table 5 describes the five most pertinent interventions performed at each PT session.

Table 4: Intervention Descriptions and Supporting Research

| Intervention | Description |
|--------------------------------------------------------------|-------------------------------------------------------------------------------------------------------------------------------------------------------------------------------------------------------------------------------------------------------------------------------------------------------------------------------------------------------------------------------------------------------------------------------------------------------------------------------------------------------------------------------|
| 1. Patient education | The subject was educated and instructed on diaphragmatic breathing, HEP, posture, proper body mechanics, and Empi unit (TENS unit) home use. A systematic review and meta-analysis by Gadotti <i>et al.</i> found that subjects with cervicogenic HA had impaired neck proprioception and altered head postures. ¹¹ Postural education is often incorporated in PT treatments for patients with cervical radiculopathy and cervicogenic HA. ⁵⁻⁸ |
| 2. Soft tissue massage (STM) | STM was performed on the subject's upper trapezius bilaterally, between medial borders of scapula, suboccipitals, supraorbital and temporal regions of forehead, masseters, and temporalis muscle to address pain, tenderness and trigger points. Progression was based on subject's chief complaint during therapy session and focused on area of significant discomfort. Rodeghero and Smith demonstrated the potential for HA symptom improvement with STM. ⁶ |
| 3. Electric stimulation (IFC- Interferential current) | High frequency electric stimulation modulated subject's pain through the Gate Theory of pain control. The electrodes were applied to the subject's bilateral upper trapezius muscles, suboccipital muscles, and medial borders of the scapulae and the intensity was adjusted to subject tolerance. This intervention was discontinued once the subject received a home unit. |
| 4. Therapeutic exercise | Various exercises were taught and performed by the subject to increase bilateral upper extremity strength and scapular stability. Such exercises included: scapular retraction, resisted rows and shoulder extension, and active and resisted abduction. Once the subject demonstrated consistent movement quality, low energy expenditure, and ease of completion, therapeutic exercises were progressed with either repetitions or resistance. Exercise has been supported to decrease HA symptoms. ^{6,7,10,14,15} |
| 5. Joint mobilization | Mobilization of the cervical spine with grades 1-3 addressed deficits in the subject's cervical segmental hypomobility. Considerable research has been done to support joint mobilizations as a safe and effective manual therapy for HA symptom relief. ^{4-8,10,15} |
| 6. Neuromuscular re-education | Interventions included: deep neck flexor strength, endurance, prone 90/90 external rotation; each performed against gravity or with resistance. |

| | |
|---------------------------------------------------------------------------|------------------------------------------------------------------------------------------------------------------------------------------------------------------------------------------------------------------------------------------------------------------------------------------------------------------------------------------------------------------------------------------------------------------------------------------------------------------------------------------------------------------------------------------------------------------------------------------------------------------------------------------------------------------------------------------------------------------------------------------------------------------------------------------------------------------------------------------------------------------------------------------------------------------------|
| | <p>Application and use of Kinesio© tape to bilateral scapular retractors was also considered neuromuscular re-education. These interventions focused on the subject improving motor control, proprioception, and endurance of deep neck and scapular musculature to facilitate improved posture and proper movement patterns without compensatory strategies. These interventions, with the exception of Kinesio© tape, is considered a "best practice" for HA interventions as evidenced in the literature.^{5-8,10,14,15}</p> |
| <p>7. Scapular Proprioceptive Neuromuscular Facilitation (PNF)</p> | <p>D1 and D2 scapular patterns performed bilaterally facilitated scapular strength and endurance within functional movement planes to restore resting posture, enhance scapular stability, strengthen scapular retractors, and decrease use of compensatory patterns in upper trapezius muscles, anterior neck muscles, and accessory muscles. Rhythmic initiation and agonist reversal techniques were used to emphasize controlled mobility while diagonal patterns addressed specific areas of weakness and increased functional independence.</p> |
| <p>8. Nerve glides</p> | <p>Median and Ulnar nerve glides were performed bilaterally to decrease cervical radiculopathy with ULTT and resisted shoulder abduction. Cleland <i>et al.</i> (2005) demonstrated 91% clinically meaningful improvements in pain and function following a plan of care that incorporated nerve glides as one treatment component.¹⁴</p> |
| <p>9. Augmented Soft Tissue Mobilization (ASTYM) ®</p> | <p>Astym® is a non-invasive treatment that activates a regenerative response throughout dysfunctional soft tissues by encouraging the breakdown of dysfunctional tissues, activation of cells like fibroblasts, macrophages, and growth factors that facilitate the growth of healthy tissue and their proper alignment. Therefore, the Astym® process is said to detect, eliminate, or reduce inappropriate fibrosis that may be causing irritation or restrictions in movement. Astym® was performed on the forehead, bilateral temples, bilateral Sternocleidomastoid, bilateral Masseter, bilateral lateral and anterior neck, bilateral inferior jaw line, suboccipitals, upper, middle and lower trapezius, and between medial borders of the scapulae to facilitate proper tissue alignment and decrease scar tissue adhesions on forehead- most notably the supraorbital foramen and suboccipital muscles.</p> |

Table 5: Daily PT Interventions

| Intervention | Visit # | | | | | | |
|-------------------------------|---------|---|---|---|---|---|---|
| | 1 | 2 | 3 | 4 | 5 | 6 | 7 |
| Patient Education | X | | X | | | | |
| STM | X | X | X | X | | | X |
| Electrical Stimulation | X | X | | | | | |
| Therapeutic Exercise | | X | X | X | X | X | X |
| Joint Mobilization | | X | | | | X | |
| Neuromuscular Re-ed | | X | X | X | X | X | X |
| Scapular PNF | | | X | X | X | X | X |
| Nerve Glides | | | | X | X | X | |
| ASTYM | | | | | X | | X |

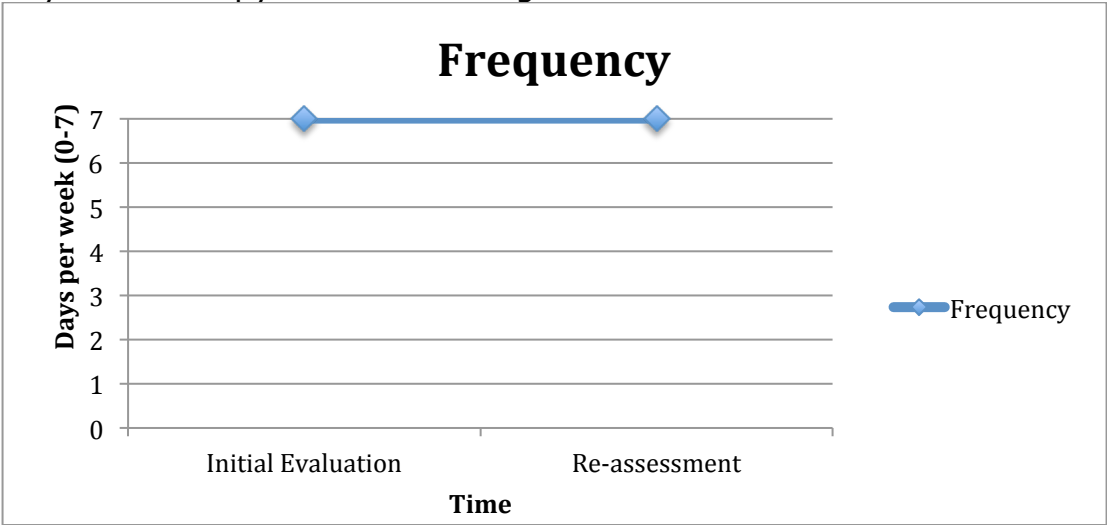
RESULTS

The subject's outcomes were re-assessed two weeks after the start of PT. The progress note was completed on visit 7 and documented the same measures as initial evaluation.

Headache Frequency

The subject's HA frequency was consistent with the report at initial evaluation of HA symptoms every day for the last 7 days. This indicates that the subject did not have any HA free days within the last week. These results are depicted in Figure 1.

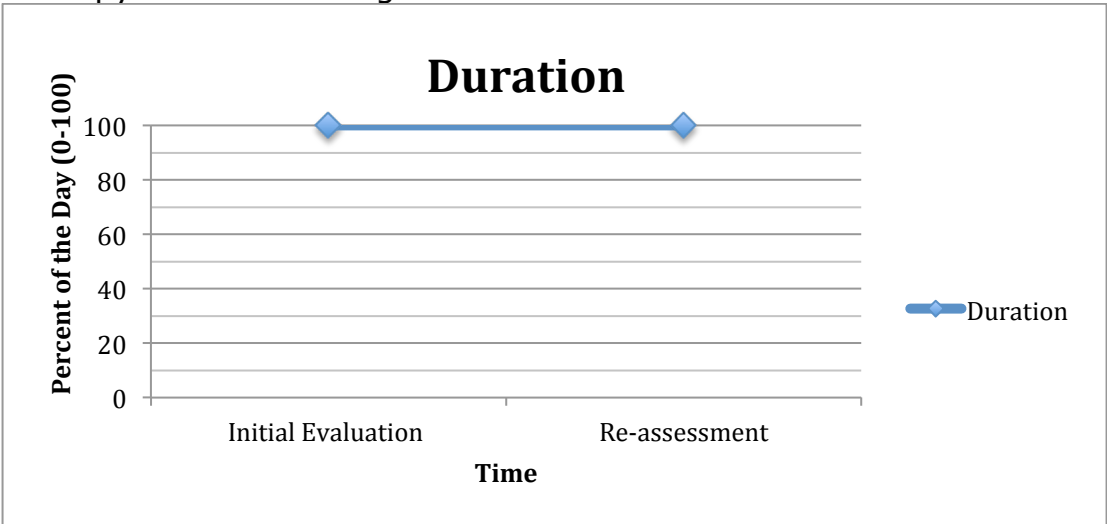
Figure 1: Headache Symptom Frequency Following a Comprehensive Physical Therapy Treatment Program



Headache Duration

At re-assessment, the subject reported HA symptoms 100% of the day, which is consistent to the report at initial evaluation. The results are summarized in Figure 2.

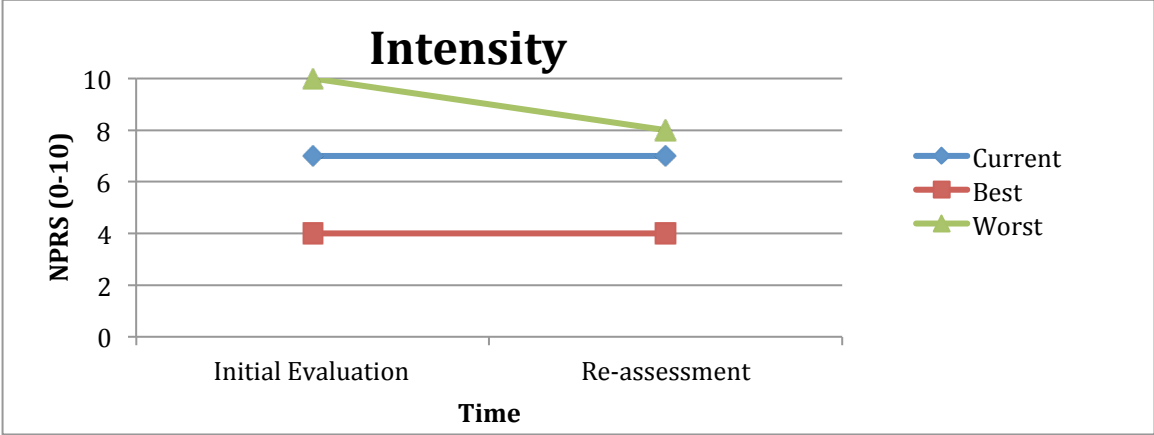
Figure 2: Headache Symptom Duration Following a Comprehensive Physical Therapy Treatment Program



Headache Intensity

While the subject’s “current” (7/0) and “best” (4/10) HA intensity rating did not decrease, her “worst” HA intensity decreased from 10/10 to 8/10. The decrease in her “worst” HA symptoms are clinically significant according to Farrar *et al.* who found the MCID to be 2 points in a chronic pain population.¹⁶ The results are summarized in Figure 3.

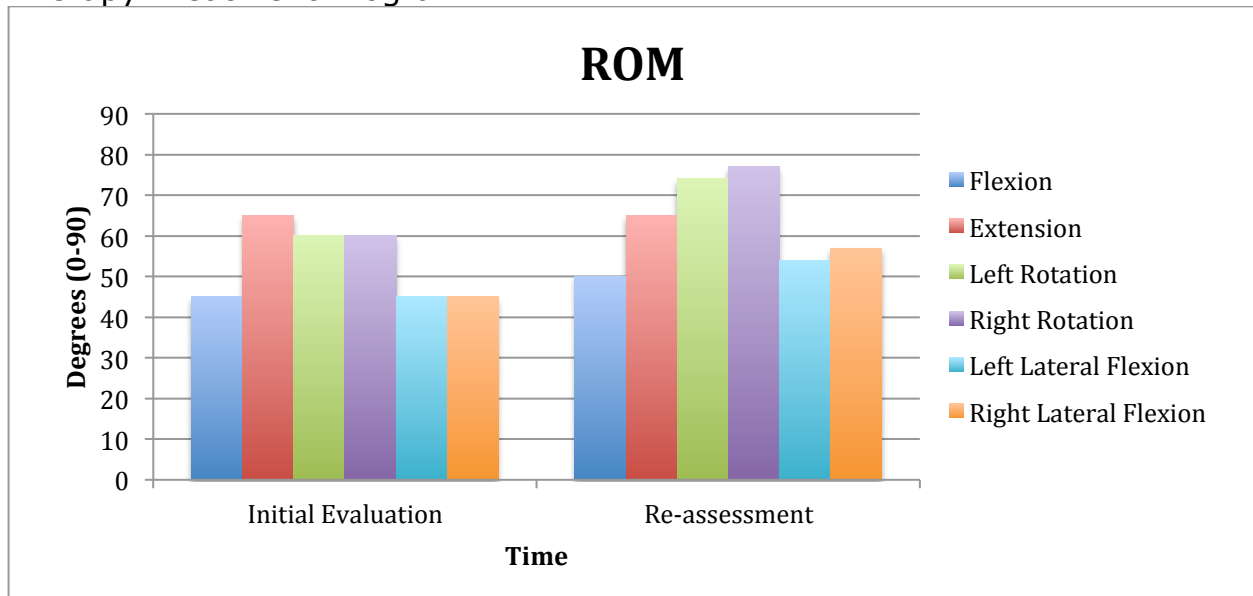
Figure 3: Headache Symptoms Intensity Following a Comprehensive Physical Therapy Treatment Program



Range of Motion

The subject was able to attain full cervical active ROM with the exception of rotation bilaterally. She still reported pain with extension but demonstrated increased ease of movements and decreased hesitancy when approaching end range. Re-assessment of cervical joint mobility revealed increased mobility at C3 and C5-C7 and hypermobility at C4. The subject’s change in cervical ROM is outlined in Figure 4.

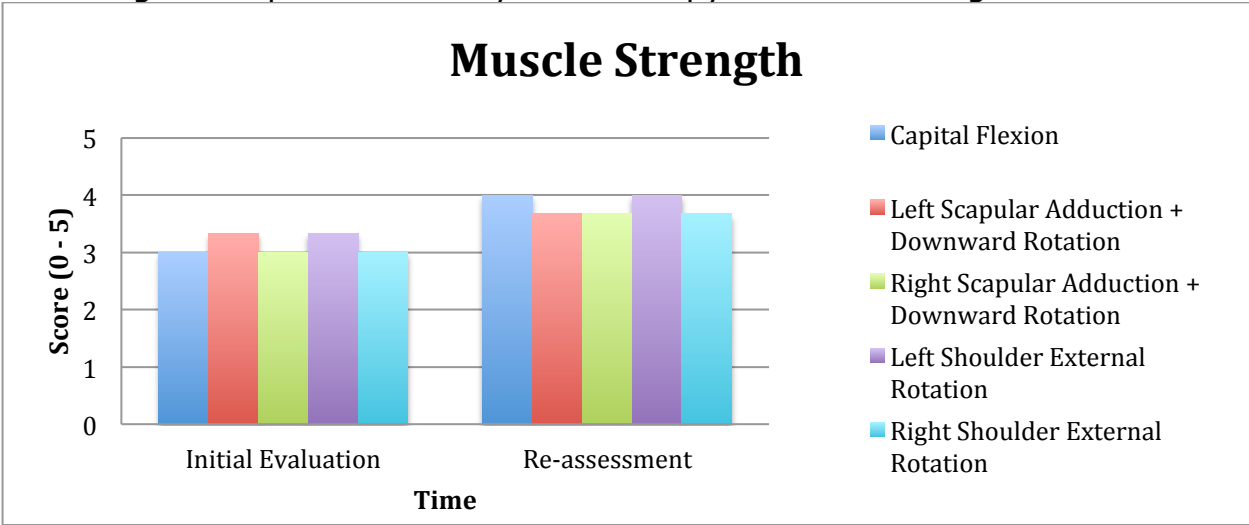
Figure 4: Cervical Range of Motion Following a Comprehensive Physical Therapy Treatment Program



Muscle Strength

The subject's progression of cervical strength, as assessed by MMT, is outlined in Figure 5. Gains in strength were made in bilateral scapular adduction + downward rotation and shoulder external rotation with significant improvement in capital flexion. While the subject demonstrated upper trapezius compensation with scapular adduction + downward rotation, she was able to complete capital flexion without upper trapezius compensation which was a marked improvement from initial evaluation.

Figure 5: Manual Muscle Strength of the Cervical and Shoulder Musculature Following a Comprehensive Physical Therapy Treatment Program



Headache Disability Inventory

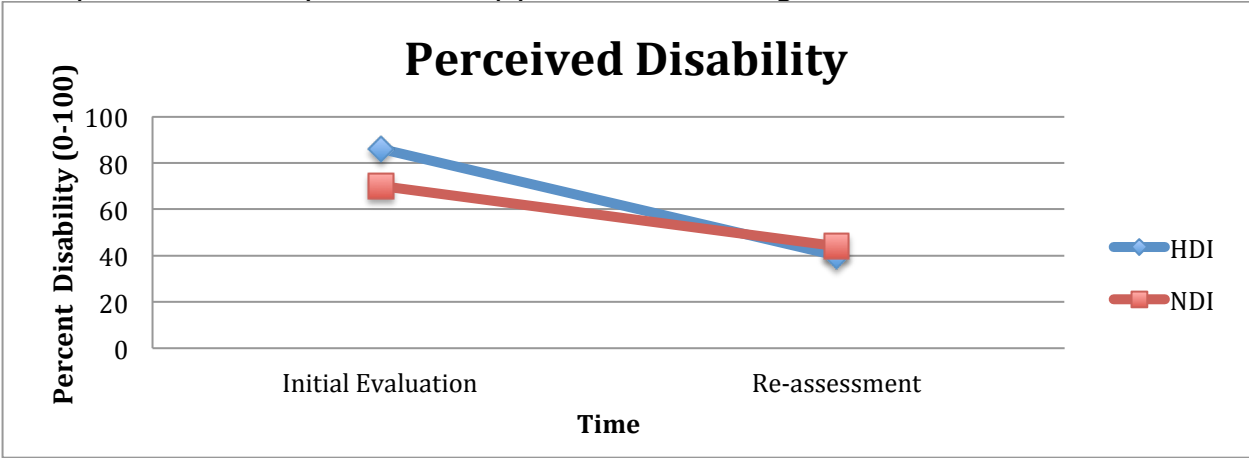
At re-assessment, the subject’s HDI score decreased by 46 points which is a clinically significant change according to Jacobson *et al.* who found the MCID to be 29 points.²¹ The self-reported outcome measure indicated a significant decrease of perceived disability in the following areas: feeling that the subject would have control of her headaches, limiting socializing due to headaches, and difficulty focusing attention away from headaches and onto other things. The results are outlined in Figure 6.

Neck Disability Index

At re-assessment, the subject’s NDI score decreased by 26% which is a clinically significant change according to Cleland *et al.* (2008) who found the MCID to be 19%.²³ The self-reported outcome measure indicated a

decrease in perceived disability in the following areas: pain intensity, work, and recreation. The results are outlined in Figure 6.

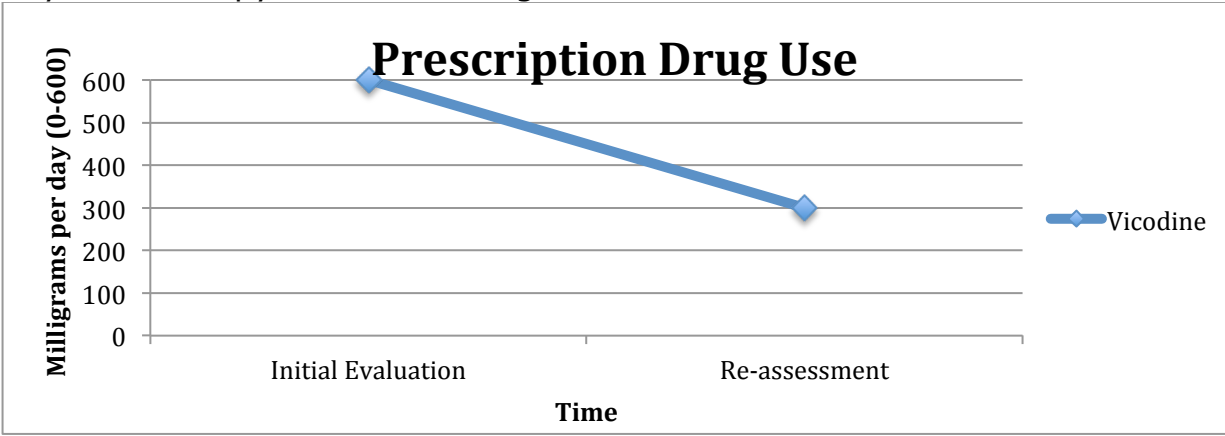
Figure 6: Perceived Disability as Measured by the HDI and NDI Following a Comprehensive Physical Therapy Treatment Program



Prescription Drug Use

Self-reported prescription drug use decreased by 50% from 600mg per day to 300mg per day. This is outlined in Figure 7.

Figure 7: Self-reported Prescription Drug Use Following a Comprehensive Physical Therapy Treatment Program



Functional Goals

At the time of re-assessment, the subject was able to look over her left shoulder without pain, which allowed her to drive up to 15 minutes. She also improved her ability to self-manage HA symptoms, which allowed her to become more socially active.

DISCUSSION

The purpose of this case report is to describe the interventions and outcomes of a comprehensive PT treatment program that emphasized addressing musculoskeletal deficits and increasing neuromuscular control, which was theorized to decrease HA symptoms for a patient with overlapping HA diagnoses. The described case study is a unique case in the literature related to PT interventions over a two-week period for a young adult female with history of migraine without aura, chronic migraine, and cervicogenic type headaches.

The decrease in her “worst” HA symptoms are clinically significant as it decreased by 2 points. It also allowed her to increase the time she could tolerate her symptoms without the use of prescription medications. Both the HDI and NDI scores decreased well below the MCID, which indicated a clinically significant change in her perceived disability.

Some inconsistencies were noted in the data. For example, the subject’s HDI and NDI scores indicated greater than 50% improvement of

perceived disability while HA intensity, frequency, and duration made little to no changes. This may be attributed to the subject's own view of her condition with high motivation and positive outlook on therapy. One theory for the improvement in cervical muscle strength in 2 weeks may be due to improved motor control and proprioception. A significant weakness to this case report was the time constraints on data collection. While the subject continued to pursue PT treatment, the author had to halt data collection due to conclusion of clinical rotation.

Verbal follow up from the subject was obtained two and a half months after data collection. The subject believed that she was 50% improved and reported her pain as localized to the forehead just superior to the eyebrows bilaterally and in the right shoulder blade along the superomedial border. She also reported that she continued to have a hard time concentrating and being a passenger in a vehicle due to the external stimuli and the bouncing movement. She was taking a class at the local college and had attempted some photography.

CONCLUSION

This case report supports the hypothesis that it is possible to influence HA symptoms with a comprehensive PT program that directly address the subject's functional limitations, musculoskeletal deficits, and neuromuscular

integration to positively influence one's quality of life and perceived disability despite complex and overlapping HA diagnoses.

REFERENCES

1. Smitherman TA, Burch R, Sheikh H, Loder E. The prevalence, impact, and treatment of migraine and severe headaches in the United States: a review of statistics from national surveillance studies. *Headache*. 2013;53(3):427-436.
2. *The International Classification of Headache Disorders*. Vol 24(Suppl 1). 2nd ed2004.
3. Racicki S, Gerwin S, DiClaudio S, Reinmann S, Donaldson M. Conservative physical therapy management for the treatment of cervicogenic headache: a systematic review. *J Man Manip Ther*. 2013;21(2):113-124.
4. Biondi DM. Physical treatments for headache: a structured review. *Headache*. 2005;45(6):738-746.
5. Sharma A, Hameed UA, Grover S. Multimodal therapy in cervicogenic headache -- a randomized controlled trial. *Indian Journal of Physiotherapy & Occupational Therapy*. 2011;5(1):9-13.
6. Rodeghero J, Smith AR. Role of manual physical therapy and specific exercise intervention in the treatment of a patient with cervicogenic headaches: a case report. *J Man Manip Ther*. 2006;14(3):159-167.
7. Jull G, Trott P, Potter H, et al. A randomized controlled trial of exercise and manipulative therapy for cervicogenic headache. *Spine*. 2002;27(17):1835-1843.
8. Castien R, Blankenstein A, Van Der Windt D, Heymans M, Dekker J. The working mechanism of manual therapy in participants with chronic tension-type headache. *J Orthop Sports Phys Ther*. 2013;43(10):693-699.
9. Fleming R, Forsythe S, Cook C. Influential variables associated with outcomes in patients with cervicogenic headache. *J Man Manip Ther*. 2007;15(3):155-164.
10. Mintken PE, Cleland J. In a 32-year-old woman with chronic neck pain and headaches, will an exercise regimen be beneficial for reducing her reports of neck pain and headaches? *Phys Ther*. 2012;92(5):645-651.
11. Gadotti IC, Olivo SA, Magee DJ. Cervical musculoskeletal impairments in cervicogenic headache: a systematic review and a meta-analysis. *Phys Ther Rev*. 2008;13(3):149-166.
12. Blizzard L, Grimmer K, Dwyer T. Validity of a measure of the frequency of headaches with overt neck involvement, and reliability of measurement of cervical spine anthropometric and muscle performance factors. *Arch Phys Med Rehabil*. 2000;81:1204-1210.
13. Andrasik F, Lipchik GL, McCrory DC, Wittrock DA. Outcome measurement in behavioral headache research: headache parameters and psychosocial outcomes. *Headache*. 2005;45(5):429-437.

14. Cleland JA, Whitman JM, Fritz JM, Palmer JA. Manual physical therapy, cervical traction, and strengthening exercises in patients with cervical radiculopathy: A case series. *J Orthop Sports Phys Ther.* 2005;35(12):802-811.
15. Young IA, Michener LA, Cleland JA, Aguilera AJ, Snyder AR. Manual therapy, exercise, and traction for patients with cervical radiculopathy: a randomized clinical trial. *Phys Ther.* 2009;89(7):632-642.
16. Farrar J, Young J, LaMoreaux L, Werth J, Poole R. Clinical importance of changes in chronic pain intensity measured on an 11-point numerical pain rating scale. *Pain.* 2001;94(2):149-158.
17. Jensen M, McFarland C. Increasing the reliability and validity of pain intensity measurement in chronic pain patients. *Pain.* 1993;55(2):195-203.
18. Herr K, Spratt K, Mobily P, Richardson G. Pain intensity assessment in older adults: use of experimental pain to compare psychometric properties and usability of selected pain scales with younger adults. *Clin J Pain.* 2004;20(4):207-219.
19. Bandy W, Reese N. *Joint Range of Motion and Muscle Length Testing.* 2nd ed: Saunders; 2009.
20. Hislop H, Montgomery J. *Daniels and Worthingham's Muscle Testing: Techniques of Manual Examination, 8e.* 8 edition ed: Saunders; 2007.
21. Jacobson G, Ramadan N, Aggarwal S, Newman C. The Henry Ford Hospital Headache Disability Inventory (HDI). *Neurology.* 1994(44):837-842.
22. McCarthy M, Grevitt M, Silcocks P, Hobbs G. The reliability of the Vernon and Mior neck disability index, and its validity compared with the short form-36 health survey questionnaire. *Eur Spine J.* 2007;16(12):2111-2117.
23. Cleland JA, Childs JA, Whitman JM. Psychometric properties of the neck disability index and numeric pain rating scale in patients with mechanical neck pain. *Arch Phys Med Rehabil.* 2008;89(1):69-74.
24. Jull GA, Stanton WR. Predictors of responsiveness to physiotherapy management of cervicogenic headache. *Cephalalgia.* 2005;25(2):101-108.